

GLYPHOSATE-BASED HERBICIDE ALTERS THE HISTOLOGICAL STRUCTURE OF GILLS OF TWO ECONOMICALLY IMPORTANT CYPRINID SPECIES (COMMON CARP, *CYPRINUS CARPIO* AND BIGHEAD CARP, *ARISTICHTHYS NOBILIS*)

GEORGIEVA, E.¹ – YANCHEVA, V.^{2*} – VELCHEVA, I.² – MOLLOV, I.² – TODOROVA, K.³ – TOMOV, S.⁴ – TSVETANOVA, V.⁵ – STOYANOVA, S.¹

¹*Department of Developmental Biology, Faculty of Biology, Plovdiv University, 4000 Plovdiv, Bulgaria*

²*Department of Ecology and Environmental Conservation, Faculty of Biology, Plovdiv University, 4000 Plovdiv, Bulgaria*

³*Lyuben Karavelov Branch, Plovdiv University, 6600 Kardzhali, Bulgaria*

⁴*Department of Urology and General Medicine, Medical University, 4000 Plovdiv, Bulgaria*

⁵*Regional Accredited Laboratory, Executive Environment Agency, Ministry of Environment and Water, 4000 Plovdiv, Bulgaria*

**Corresponding author*

e-mail: veselayancheva@yahoo.com; phone: +35-932-261-540

(Received 4th Dec 2017; Accepted 7th Mar 2018)

Abstract. The present study primarily aims to investigate the histopathological effects which a glyphosate based herbicide could cause on the gills of two economically important Cyprinid fish (common carp and bighead carp), and to determine which species is more sensitive in terms of glyphosate contamination. The pesticide concentrations tested in laboratory conditions were decreasing (72 mg/l, 40 mg/l and 20 mg/l) and prepared by dilution of the stock solution of the commercial product used in plant protection. The experiment was short-term of 96 h. In general, the herbicide caused different pathological alterations in the fish gills, such as lamellar lifting, edema, proliferation of the glandular cells and epithelium, covering the gill filament, fusion, vasodilatation of the secondary lamellae and aneurysms. In addition, we observed a tendency towards the enhancement of the gill histological changes which degree of expression was proportional to the increasing pesticide concentrations. However, bighead carp was more sensitive compared to common carp when it comes to the tested chemical and the alterations in the gill histological structure were more pronounced.

Keywords: *histopathology, fish, biomarkers, pesticide, contamination*

Introduction

Pollution of water is mainly due to contamination with hazardous chemicals from agricultural runoff and waste water from household and different industries. One of the major chemicals from agricultural runoff are pesticides which play an important role in the agricultural productivity and have been widely applied to protect agricultural crops. On the other hand, they can cause severe damage to non-target organisms, both in the terrestrial and aquatic environment (Magar and Shaik, 2013; Grung et al., 2015).

The glyphosate herbicides, post-emergent herbicides with a broad-spectrum and low selectivity, have been intensively applied on numerous field cultures, urban and industrial areas to control unwanted plants, including the macrophytes in aquatic systems (Nedelkoska and Low, 2004; Kolpin et al., 2006; Çavas and Konen, 2007). In addition, most of the commercial formulations of herbicide-based glyphosate consist of glyphosate isopropylamine salt (IPA) and a surfactant in order to increase the herbicide's efficacy (Tsui and Chu, 2003).

Fish are among the group of non-target aquatic organisms which represent the largest and most diverse group of vertebrates and a number of characteristics make them excellent experimental models for toxicological research (Raisuddin and Lee, 2008). In this sense, fish are often used as indicators of pesticide water contamination due to the fact that they respond to it with physiological and behavioral alterations (Banaee et al., 2011, 2013; Murthy et al., 2013).

Cyprinidae is a family of freshwater fish which consists of 1600 species. This makes it the most diverse family. The most popular species, common carp (*Cyprinus carpio* Linnaeus, 1758) is a wide-spread and economically important fish which has immense significance for aquaculture. Carp is also very popular in sports fishing due to its fast growth rate, hardiness and prolific breeding in confined water. Furthermore, it has been proposed as a test organism in toxicological research because it is relatively insensitive and as a consequence, survives and accumulates contaminants even at heavily polluted sites (Snyder et al., 2004; Brumbaugh et al., 2005; Reynaud and Deschaux, 2005; Oruc and Usta, 2007; Reynders et al., 2008; De Boeck et al., 2010; Georgieva et al., 2014; Stoyanova et al., 2015). Bighead carp (*Aristichthys nobilis* Richardson, 1845) is another Cyprinid species which has become popular in aquaculture in recent years. It is usually bred with common carp and silver carp (*Hypophthalmichthys molitrix* Valenciennes, 1844) for better results. Similarly to common carp, it grows quite rapidly and its meat has started increasingly to be preferred for consumption in more countries (Čihař, 1975; Karapetkova and Jivkov, 2010). However, it has not been that widely studied in terms of the effects of different pollutants compared to common carp (Li et al., 2005; Hu et al., 2010; Li et al., 2014). Thus, in the present study we propose this Cyprinid species together with common carp as model species for ecotoxicological research.

Viana et al. (2013) suggest that the biomonitoring and risk assessment processes should include analyses at different levels of biological organization, from sub-cellular and cellular analysis of tissues and organs, to those of population and community levels. Therefore, Van der Oost et al. (2003) also suggest the use of biomarkers as biological indicators from an exposure to a stressor responding in various ways which can be successfully applied. In this sense, according to Van Dyk and Pieterse (2008) histology is an important diagnostic and sensitive tool to detect the direct effects of chemical compounds on target organs and can therefore, be used to assess the health of fish populations in contaminated aquatic systems. The advantage of histology as a biomarker lies in its intermediate location with regard to the level of biological organization. Furthermore, the histological changes appear as a medium-term response to sub-lethal stressors, and histology provides a rapid method to detect the effects of irritants, especially chronic ones, in various tissues and organs (Devi and Mishra, 2013; Binukumari and Vasanthi, 2014). Thus, the histopathological changes due to various pesticides have been extensively studied in different fish species (Ullah and Zorriehzahra, 2015).

The gills are efficient tools for monitoring of aquatic ecosystems because of their large area which is in contact with the water and their high permeability (Oliveira Ribeiro et al., 2005; Evans et al., 2005; Vigliano et al., 2006). They are the main respiratory organ and have a large surface area, a thin water-blood diffusion distance and play an important role in osmoregulation and acid base equilibrium. In fish, the gills are also the main target organs of xenobiotic molecules. The changes in gill tissue affect respiration and ion uptake in freshwater fish (Fernandes and Mazon, 2003; Fanta et al., 2003; Bhuvaneshwari et al., 2015). Moreover, Nowak (1992) states that the gill histological changes, such as hyperplasia and hypertrophy, epithelial lifting, and aneurysms have been more pronounced in this particular organ after pesticide exposure.

The impact of glyphosate on fish has been studied mainly in commercial products which included other active ingredients and not just glyphosate itself (Neškovic et al., 1996; Ramirez-Duarte et al., 2008; Ayoola, 2008). We did not find any data regarding the effects of glyphosate on bighead carp which is economically important species in aquaculture and it is artificially bred together with common carp for better results. Thus, the present study primarily aims to investigate the histological effects which a glyphosate based herbicide could possibly cause on the gills of two economically important Cyprinid freshwater fish (common carp and bighead carp) and to determine which species is more sensitive in terms of pesticide contamination. The second objective aims to establish the degree of expression of each histological alteration which could be observed.

Material and Methods

Chemicals and experimental setup

The test pesticide in the present study was a glyphosate (IUPAC name N-(phosphonomethyl)-glycine) based herbicide which is used to control grasses, herbaceous plants, including deep-rooted perennial weeds, some broadleaf trees, shrubs, and conifers (Standing Committee on Plant Health, 2001). We used decreasing glyphosate concentrations of 72 mg/l, 40 mg/l and 20 mg/l under laboratory conditions for a total acute period of 96 h. All three concentrations were prepared in advance by dilution of the commercial product stock solution used in plant protection, given by the company which produces the chemical. The concentrations we used are lower than those actually applied in agriculture as a particular amount of the chemicals enter the water ecosystems through rainfall and wind drift.

Forty healthy common and bighead carps were obtained from the Institute of Fisheries and Aquaculture, Bulgaria where the fish are reared under strict controlled conditions. The fish were of the same size-group (mean length 17.6 cm \pm 2.9 and mean body mass 46.3 g \pm 8.4 for common carp and mean length 18.65 cm \pm 1.33 and mean body mass 53.02 g \pm 5.3 for bighead carp) with no observed external pathological abnormalities. After transportation, the fish were moved in 100 l glass aquaria with chlorine-free tap water (by evaporation) to acclimatize for a week. They were randomly divided into four groups, including control (n=10) and not fed during the experiment.

The water physico-chemical characteristics, such as pH, temperature, dissolved oxygen, oxygen saturation and conductivity were measured once per day according to a standard procedure (APHA, 2005). All experiments were conducted in accordance with Directive 2010/63/EU.

Histopathological analysis

The fish dissection was performed according to the procedures given in the EMERGE Protocol (Rosseland et al., 2003). The samples were placed in vials with 10% neutral buffered formaldehyde solution (pH 7.0). Then they were rinsed in tap water, dehydrated in a graded series of ethanol concentrations, cleared in xylene, embedded in paraffin wax with melting point of 54–56 °C, sectioned to a thickness of 5–7 µm using a rotary microtome (Leica RM 2125) and mounted on sterilized glass slides. The sections were then deparaffinised, stained with hematoxylin and eosin (H&E) for histological examinations and prepared for light microscopy analysis (Romeis, 1989).

Semi-quantitative scoring

Ten paraffin sections were produced from the gills of each specimen. Each section was taken from a different location from the paraffin block, instead of in series. The histological alterations in the gill structure of each paraffin section were analyzed by observing the whole gill surface. The degree of expression was studied, including the corresponding changes in the gill surface in relation to the normal histological structure. The histological alterations in the gill epithelium were determined semi-quantitatively by using the grading system of Pierce et al. (1978) and Zimmerli et al. (2007) which we combined and modified. Each grade represented specific histological characteristics and was categorized as follows:

- (0) – no histological alterations which represented normal histological structure;
- (1) – mild histological alterations;
- (2) – moderate histological alterations;
- (3) – severe histological alterations;
- (4) – very severe histological alterations in the gill surface architecture.

Statistical analysis

The statistical program which was used was Graph Pad Prism 7 for Windows. In order to study the differences between the degree of expression of each histological alteration between the control and treated with different glyphosate concentrations groups, *t*-test was applied. *P* value was set at 0.05. This was possible as for each degree of expression a numerical value from 0 to 4 was given. Ten fish from each test group and species were analyzed. The results are presented as average.

Results and Discussion

No histopathological changes were observed in the control fish gills. Gill structural details of the control carps are shown in *Figure 1A* and *2A*. With regard to the grading system, proposed as the control carp histological characteristics, these were evaluated as relatively normal (0). Comparing both Cyprinids exposed to glyphosate, we found in the gill structure proliferative changes (lamellar lifting, edema, proliferation of epithelial covering the filament and glandular cells, proliferation of cartilage, fusion), degenerative changes and changes in the circulatory system (vasodilatation of the primary sinus and blood vessels in the secondary lamellae) which all varied in their degree of expression (*Figure 1, 2*).

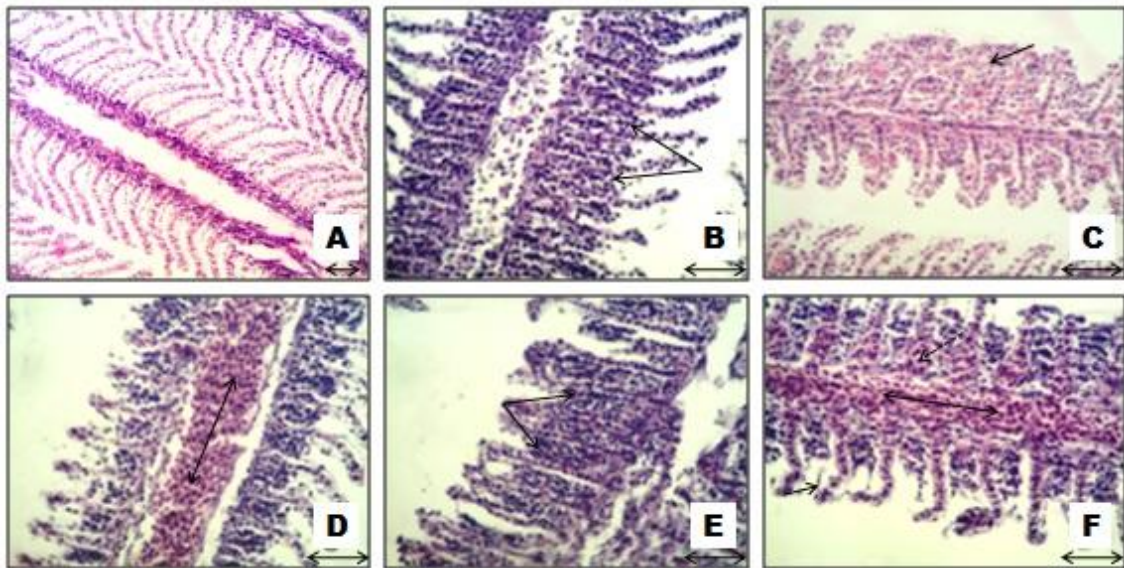


Figure 1. Histopathological alterations in common carp gills, (H&E): A – control group fish gills, x200; B – proliferation of the gill epithelium, x400; C – fusion of the secondary lamellae, x400; D – vasodilatation of the central venous sinus, x400; E – epithelium proliferation, x400; F – lamellar lifting, vasodilatation of the central venous sinus and the secondary lamellae (dashed arrow), x400

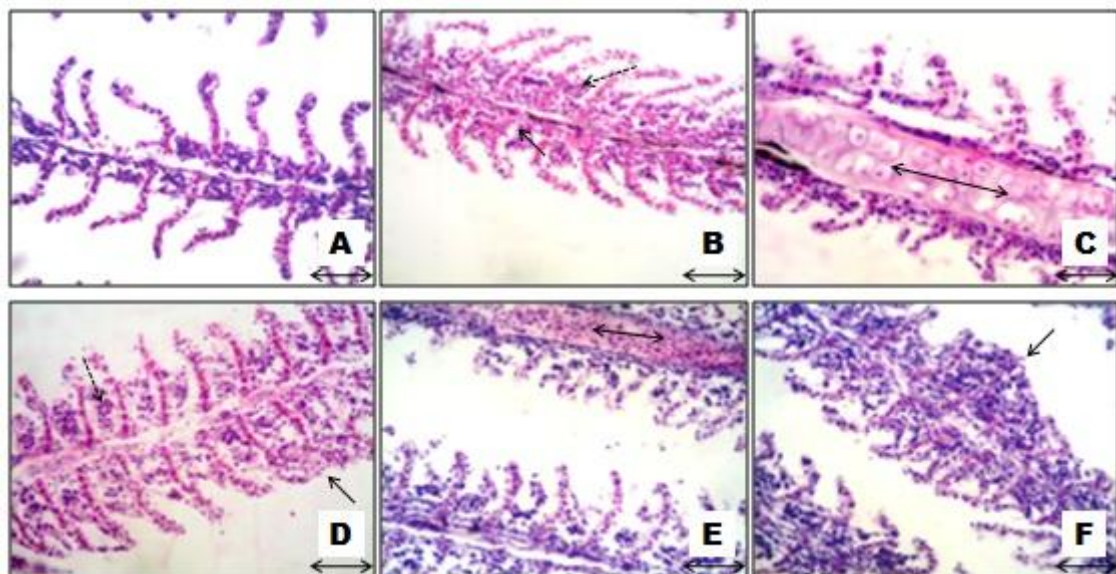


Figure 2. Histopathological alterations in bighead carp gills, (H&E), x400: A – control group fish gills; B – proliferation of the gill epithelium (dashed arrow) and edema; C – proliferation of the cartilage tissue; D – proliferation of the gill epithelium (dashed arrow) and fusion; E – vasodilatation of the central venous sinus; F – fusion of the secondary lamellae

For the degree of expression of each alteration the statistical analysis showed that there was a significant difference ($P < 0.05$) between the control for both Cyprinids and all test groups exposed to glyphosate (72 mg/l, 40 mg/l and 20 mg/l).

Table 1 shows that lamellar lifting and edema were more pronounced – in severe and very severe degree of expression in both tested species, when increasing the concentrations of glyphosate. We consider that lamellar lifting and edema actually represent a compensatory-adaptive mechanism which increased the distance between the epithelium and blood vessels in the secondary lamellae. Hence, the changes found in the fish gills could slow down the oxygen access into the blood circulatory system which in turn would result in a gas exchange limit. As reported by Schwaiger et al. (2004) and Camargo and Martinez (2007) lamellar lifting and edema could lead to oxygen deficiency and subsequent oxidative stress for the fish. In addition, we found proliferation of the filamentous epithelium as probably another type of compensatory-adaptive mechanism in the fish gills exposed at all herbicide concentrations. It increased the thickness and the layers of the different epithelial cells which could likely delay the toxicant access through the gills. Proliferation of the filamentous epithelium was expressed mainly in a severe degree in the gills of common carp, while in the bighead carp gills it was found in a very severe degree of expression. Furthermore, proliferation of the connective cartilage tissue, leading to increased volume of gill filaments, was presented only in the gills of bighead carp which showed specificity in regards to glyphosate contamination. Ramah (2011) also reported cartilage hyperplasia in *Ctenopharyngodon idella* gills under herbicide exposure but in general this histopathological alteration is not often found in fish gills under the influence of different pesticides. Fusion as a more severe form of proliferation of the filamentous stratified epithelium was presented in a similar degree of expression in both tested species. In terms of the proliferative changes, we consider that bighead carp showed higher sensitivity under the influence of glyphosate compared to common carp because we also observed very severe proliferation of the filamentous epithelium and cartilage hyperplasia.

We found changes in the gills circulatory system such as vasodilation in the secondary lamellae and the main venous sinus. Vasodilatation was presented in a moderate degree of expression in the bighead carp gills at all glyphosate concentrations, while this change was in such a degree in the common carp gills only at the highest glyphosate concentration (*Table 1, Figure 1, 2*). Therefore, we consider that bighead carp had higher sensitivity in relation to the pesticide effects which could be found even at the lower concentrations of the toxicant. It also enhanced the blood cell flow and increased the internal pressure of the blood vessels. However, aneurysms in the secondary lamellae were observed only in the common carp gills. Cengiz (2006) also reported aneurysms in the secondary lamellae in common carp gills under the effect of deltamethrin.

We did not find aneurysms in the bighead carp gills in our previous studies (unpublished data) related to pesticides effects, either. Thus, we suggest that the bighead carp blood vessels could have higher resistance to pesticide contamination. Despite of the internal pressure and vasodilatation in blood vessels, aneurysms in the secondary lamellae of the bighead carp gills did not occur (*Table 1*).

Degenerative changes in the gills were also presented in both fish species which were found in a moderate and severe degree in the bighead carp gills at all glyphosate concentrations, while they were presented in a severe degree in the common carp gills only at 72 mg/l glyphosate (*Table 1*).

Table 1. Histopathological alterations in common carp and bighead carp gills caused by the test herbicide

Gills histopathological alterations	Concentration herbicide							
	Common carp				Bighead carp			
	Control	20 mg/l	40 mg/l	72 mg/l	Control	20 mg/l	40 mg/l	72 mg/l
Lamellar lifting	1	3	4	4	1	2*	4	4*
Edema	0	2	3	4	0	2	3	4
Proliferation of stratified epithelium	0	<i>3**</i>	3	<i>3**</i>	0	<i>2**</i>	3	<i>4**</i>
Proliferation of glandular cells	0	1*	2	3*	0	1	2	2
Fusion	0	0*	1	2*	0	0*	1	2*
Proliferation of cartilage tissue	0	<i>0**</i>	0	<i>0**</i>	0	<i>2**</i>	2	<i>3**</i>
Degeneration of gill epithelium	0	<i>0**</i>	<i>1**</i>	3	0	<i>2**</i>	<i>3**</i>	3
Vasodilatation of secondary lamellae	0	0*	1	2*	0	2	2	2
Vasodilatation of central venous sinus	0	1	1	2	0	2	2	2
Aneurysms	0	0	<i>2**</i>	<i>3**</i>	0	0	<i>0**</i>	<i>0**</i>

(0) – no histological alterations which represented normal histological structure; (1) – mild histological alterations; (2) – moderate histological alterations; (3) – severe histological alterations; (4) – very severe histological alterations of the gill surface architecture

* **Bold** – Significant differences in the degree of expression of each histological alteration for common carp and bighead carp separately after exposure to 20, 40 and 72 mg/l (P < 0.05)

** *Italic* – Significant differences in the degree of expression of each histological alteration between common carp and bighead carp together after exposure to 20, 40 and 72 mg/l (P < 0.05)

The high degree of degenerative changes could lead to thinning of the epithelial filaments and secondary lamellae, which on the other hand could lead to more rapid toxicant penetration. Similarly to us, Santhakumar et al. (2001) reported histopathological effects such as degenerative and necrotic changes in fish gills under the influence of sublethal concentrations of monocrotophos. Ghanbahadur et al. (2015) found degenerative alterations and necrosis in *Rasbora daniconius* gills after acute and chronic endosulfan exposure. Such results were also reported in common carp gills under lindan exposure by Binukumari and Vasanthi (2014) and under deltamethrin exposure by Cengiz (2006), respectively. The observed proliferative and degenerative histopathological alterations in this study suggest the development of a two-way process in the fish gills under the glyphosate influence. On one hand, the toxicant induced a compensatory-adaptive process which was related to transport delay of the toxicant by lamellar lifting and edema, as well as induced process of mitosis in the gill epithelium and cartilage in the bighead carp gill. On the other hand, glyphosate induced degenerative changes which were related with necrotic processes. Regarding the two Cyprinids separately the t-test proved significant differences ($P < 0.05$) for the degree of expression of proliferation of glandular cells between the fish exposed to 20 mg/l and 72 mg/l. Similar differences were also proved for fusion and vasodilatation of secondary lamellae between 20 mg/l and 72 mg/l (Table 1). Regarding the degree of expression of the histological alterations in bighead carp, the statistical analysis proved significant differences for lamellar lifting and fusion between the groups treated again with the lowest and highest glyphosate concentrations.

Comparing the two fish species together, statistically significant differences were found in the degree of proliferation of stratified epithelium in common carp and bighead carp between 20 mg/l and 72 mg/l. These were also found for proliferation of cartilage tissue and aneurysms between 20 mg/l and 72 mg/l, and for degeneration of gill epithelium but between 20 mg/l and 40 mg/l ($P < 0.05$).

In sum, we observed proliferative and degenerative changes in the bighead carp gills at all glyphosate concentrations. However, pronounced proliferative histopathological alterations in the common carp gills were found at the highest pesticide concentration. These results showed bighead carp as a more sensitive species in comparison to common carp. Therefore, we believe that bighead carp is an appropriate species for ecotoxicological tests, as well as a good bioindicator for pesticide pollution of water bodies. We consider that the results from such *ex situ* experiments could be applied for better plant protection practices, in the field of water legislation for reducing maximum allowable concentrations of organic pollutants, and the protection of freshwater fauna by using bioindicators and applying histological biomarkers. Last but not least, we suggest that further research in this particular area need to be carried out in order to better study the glyphosate toxicity in different commercial mixtures used in plant protection, and its interactions (antagonistic and synergistic) with other pollutants.

REFERENCES

- [1] APHA (2005): Standard methods for examination of water and wastewater, 21st ed. - American Public Health Association, Washington.
- [2] Ayoola, S.O. (2008): Toxicity of glyphosate herbicide on Nile tilapia (*Oreochromis niloticus*) juvenile. - African Journal of Agricultural Research 3(12): 825-834.

- [3] Banaee, M., Mirvaghefi, A.R., Mojazi Amiri, B., Rafiee, G.R., Nematdost, B. (2011): Hematological and histopathological effects of diazinon poisoning in common carp (*Cyprinus carpio*). - Iranian Journal of Natural Resources Research 64(1): 1-13.
- [4] Banaee, M., Davoodi, M.H., Zoheiri, F. (2013): Histopathological changes induced by paraquat on some tissues of gourami fish (*Trichogaster trichopterus*). - Open Veterinary Journal 3(1): 36-42.
- [5] Bhuvaneshwari, R., Padmanaban, K., Babu Rajendran, R. (2015): Histopathological alterations in muscle, liver and gill tissues of Zebra fish *Danio rerio* due to environmentally relevant concentrations of organochlorine pesticides (OCPs) and heavy metals. - International Journal of Environmental Research 9(4): 1365-1372.
- [6] Binukumari, S., Vasanthi, J. (2014): Histopathological effect of the pesticide lindane in the gill tissue of the freshwater fish, *Cyprinus carpio*. - Journal of Pharmaceutical and Biological Sciences 2(2): 165-167.
- [7] Brumbaugh, W.G., Schmitt, C.J., May, T.W. (2005): Concentrations of cadmium, lead, and zinc in fish from mining influenced waters of northeastern Oklahoma: sampling of blood, carcass, and liver for aquatic biomonitoring. - Archives of Environmental Contamination and Toxicology 49: 76-88.
- [8] Camargo, M.M., Martinez, C.B. (2007): Histopathology of gills, kidney and liver of a Neotropical fish caged in an urban stream. - Neotropical Ichthyology 5: 327-336.
- [9] Çavaş, T., Konen, S. (2007): Detection of cytogenetic and DNA damage in the peripheral goldfish (*Carassius auratus*) exposed to a glyphosate formulation using the micronucleus test and the comet assay. - Mutagenesis 22: 263-268.
- [10] Cengiz, E.I. (2006): Gill and kidney histopathology in the freshwater fish *Cyprinus carpio* after acute exposure to deltamethrin. - Environmental Toxicology and Pharmacology 22: 200-204.
- [11] Čihař, J. (1975): A color guide to familiar freshwater fishes. - Octopus books limited, Prague, pp.184.
- [12] De Boeck, G., Smolders, R., Blust, R. (2010): Copper toxicity in gibel carp *Carassius auratus gibelio*: Importance of sodium and glycogen. - Comparative Biochemistry and Physiology - Part C: Toxicology & Pharmacology 152: 332-337.
- [13] Devi, Y., Mishra, A. (2013): Study of behavioural and morphological anomalies of fry fish of fresh water teleost, *Channa punctatus* under chlorpyrifos intoxication. - The International Journal of Pharma and Bio Sciences 4: 865-874.
- [14] Directive 2010/63/EU of the European Parliament and of the Council on the protection of animals used for scientific purposes. - Official Journal of the European Union.
- [15] Evans, D.H., Piermarini, P.M., Choe, K.P. (2005): The multifunctional fish gill: dominant site of gas exchange, osmoregulation, acid-base regulation, and excretion of nitrogenous waste. - Physiological Reviews 85: 97-177.
- [16] Fanta, E., Rios, F.S., Romao, S., Vianna, A.C.C., Freiberger, S. (2003): Histopathology of the fish *Corydoras paleatus* contaminated with sublethal levels of organophosphorus in water and food. - Ecotoxicology and Environmental Safety 54(2): 119-130.
- [17] Fernandes, M.N., Mazon, A.F. (2003): Environmental pollution and fish gill morphology. - In: Val, A.L., Kapoor, B.G. (eds.) Fish adaptation. Science Publishers, Enfield, 203-231.
- [18] Georgieva, E., Stoyanova, S., Velcheva, I., Yancheva, V. (2014): Histopathological alterations in common Carp (*Cyprinus carpio* L.) gills caused by thiamethoxam. - Brazilian Archives of Biology and Technology 57(6): 991-996.
- [19] Ghanbahadur, A.G., Ghanbahadur, G.R., Ganeshwade, R.M., Wagh, S.B. (2015): Histopathological effect of organochloride endosulfan on gills of larvivorous fish *Rarbora daniconius*. - Bioscience Discovery 6(2): 121-124.
- [20] Grung, M., Lina, Y., Zhang, H., Steen, A.O., Huang, J., Zhang, G., Larssen, T. (2015): Pesticide levels and environmental risk in aquatic environments in China - a review. - Environment International 81: 87-97.

- [21] Hu, G., Dai, J., Mai, B., Luo, X., Cao, H., Wang, J., Li, F., Xu, M. (2010): Concentrations and accumulation features of organochlorine pesticides in the Baiyangdian lake freshwater food web of North China. – Archives of Environmental Contamination and Toxicology 58(3): 700-710.
- [22] Karapetkova, M., Jivkov, M. (2010): Fish in Bulgaria. – Gea-libris, Sofia, pp. 215 [in Bulgarian].
- [23] Kolpin, D.W., Thurman, E.M., Lee, E.A., Meyer, M.T., Frlong, E.T., Glassmeyer, S.T. (2006): Urban contributions of glyphosate and its degradate AMPA to streams in the United States. - Science of the Total Environment 354: 191-197.
- [24] Li, L., Xie, P., Chen, J. (2005): In vivo studies on toxin accumulation in liver and ultrastructural changes of hepatocytes of the phytoplanktivorous bighead carp i.p. - injected with extracted microcystins. - Toxicon 46(5): 533-545.
- [25] Li, W., Xie, P., He, J., Guo, X., Tuo, X., Zhang, W., Wu, L. (2014): Rapid conversion and reversible conjugation of glutathione detoxification of microcystins in bighead carp (*Aristichthys nobilis*). - Aquatic Toxicology 147: 18-25.
- [26] Magar, R.S., Shaik, A. (2013): Effect of malathion toxicity on detoxifying organ of fresh water fish *Channa punctatus*. - Journal of Pharmaceutical, Chemical and Biological Sciences 3(3): 723-728.
- [27] Murthy, K.S., Kiran, B.R., Venkateswarlu, M. (2013): A review on toxicity of pesticides in Fish. - International Journal of Open Scientific Research 1(1): 15-36.
- [28] Nedelkoska, T.V., Low, G.K.C. (2004): High-performance liquid chromatographic determination of glyphosate in water and plant material after pre-column derivatisation with 9-fluorenylmethyl chloroformate. - Analytica Chimica Acta 511: 145-153.
- [29] Neškovic, N.K., Poleksic, V., Elezovic, I., Karan, V., Budimir, M. (1996): Biochemical and histopathological effects of glyphosate on Carp, *Cyprinus carpio* L. - Bulletin of Environmental Contamination and Toxicology 56: 295-302.
- [30] Nowak, B. (1992): Histological changes in gills induced by residues of endosulfan. - Aquatic Toxicology 23: 63-84.
- [31] Oliveira Ribeiro, C.A., Vollaie, Y., Sanchez-Chardi, A., Roche, H. (2005): Bioaccumulation and the effects of organochlorine pesticides, PAH and heavy metals in the eel (*Anguilla anguilla*) at the Camargue Nature Reserve, France. - Aquatic Toxicology 74: 53-69.
- [32] Oruc, E.O., Usta, D. (2007): Evaluation of oxidative stress responses and neurotoxicity potential of diazinon in different tissues of *Cyprinus carpio*. - Environmental Toxicology and Pharmacology 23: 48-55.
- [33] Pierce, K.W., McCain, B.B., Wellings, S.R. (1978): Pathology of hepatomas and other liver abnormalities in English sole (*Parophrys vetulus*) from the Duwamish river estuary, Seattle, Washington. - Journal of the National Cancer Institute 60(6): 1445-1543.
- [34] Raisuddin, S., Lee, J.S. (2008): Fish models in impact assessment of carcinogenic potential of environmental chemical pollutants: an appraisal of hermaphroditic mangrove killifish *Kryptolebias marmoratus*. - Interdisciplinary Studies on Environmental Chemistry - Biological Responses to Chemical Pollutants 1: 7-15.
- [35] Ramah, K. (2011): Histopathological study on the effect of rice herbicides on grass carp (*Ctenopharyngodon idella*). - African Journal of Biotechnology 10(7): 1112-1116.
- [36] Ramirez-Duarte, F.W., Rondon-Barragan, I.S., Eslava-Mocha, P.R. (2008): Acute toxicity and histopathological alterations of Roundup R herbicide on “Cachama blanca” (*Piaractus brachypomus*). - Pesquisa Veterinária Brasileira 28(11): 547-554.
- [37] Reynaud, S., Deschaux, P. (2005): The effects of 3-methylcholanthrene lymphocyte proliferation in the common carp (*Cyprinus carpio* L.). - Toxicology 211: 156-164.
- [38] Reynders, H., Bervoets, L., Gelders, M., De Coen, W.M., Blust, R. (2008): Accumulation and effects of metals in caged carp and resident roach along a metal pollution gradient in Flanders, Belgium. - Science of the Total Environment 391: 82-95.

- [39] Romeis, B. (1989): Mikroskopische technik. - Urban und Schwarzenberg, Munchen, pp. 697.
- [40] Rosseland, B.O., Massabuau, J.C., Grimalt, J., Hofer, R., Lackner, R., Raddum, G., Rognerud, S., Vives, I. (2003): Fish ecotoxicology: European mountain lake ecosystems regionalisation, diagnostic and socio-economic evaluation (EMERGE). Fish sampling manual for live fish. - Norwegian Institute for Water Research (NIVA), Oslo, pp. 8.
- [41] Santhakumar, M., Balaji, M., Ramudu, K. (2001): Gill lesions in the perch, *Anabas testudineus*, exposed to monocrotophos. - *Journal of Environmental Biology* 22: 78-90.
- [42] Schwaiger, J., Ferling, H., Mallow, U., Wintermayr, H., Negele, R.D. (2004): Toxic effects of the non-steroidal anti-inflammatory drug diclofenac. Part I. Histopathological alterations and bioaccumulation in rainbow trout. - *Aquatic Toxicology* 68: 141-150.
- [43] Snyder, E.M., Snyder, S.A., Kelly, K.L., Gross, T.S., Villeneuve, D.L., Fitzgerald, S.D., Villalobos, S.A., Giesy, J.P. (2004): Reproductive responses of common carp (*Cyprinus carpio*) exposed in cages to influent of the Las Vegas Wash in Lake Mead, Nevada, from late winter to early spring. - *Environmental Science & Technology* 38: 6385-6395.
- [44] Standing Committee on Plant Health. (2001): Review report for the active substance glyphosate. Finalized in the Standing Committee on Plant Health at its meeting on 29 June 2001 in view of the inclusion of glyphosate in Annex I of Directive 91/414/EEC.
- [45] Stoyanova, S., Yancheva, V., Velcheva, I., Uchikova, E., Georgieva, E. (2015): Histological alterations in common carp (*Cyprinus carpio* Linnaeus, 1758) gills as potential biomarkers for fungicide contamination. - *Brazilian Archives of Biology and Technology* 58(5): 757-764.
- [46] Tsui, M.T.K., Chu, L.M. (2003): Aquatic toxicity of glyphosate-based formulations: comparison between different organisms and the effects of environmental factors. - *Chemosphere* 52: 1189-1197.
- [47] Ullah, S., Zorriehzahra, M.J. (2015): Ecotoxicology: a review of pesticides induced toxicity in fish. - *Advances in Animal and Veterinary Sciences* 3(1): 40-57.
- [48] Van der Oost, R., Beyer, J., Vermeulen, N.P.E. (2003): Fish bioaccumulation and biomarkers in environmental risk assessment: A review. - *Environmental Toxicology and Pharmacology* 13: 57-149.
- [49] Van Dyk, J.C., Pieterse, G.M. (2008): A histo-morphological study of the testis of the sharptooth catfish (*Clarias gariepinus*) as reference for future toxicological assessments. - *Journal of Applied Ichthyology* 24: 415-422.
- [50] Viana, A.P., Frédou, F.L., Da Silva Montes, C., Rocha, R.M. (2013): Fish histopathology and catalase activity as biomarkers of the environmental quality of the industrial district on the Amazon estuary, Brazil. - *Acta Scientiarum* 35(3): 395-401.
- [51] Vigliano, F.A., Aleman, N., Quiroga, M.I., Nieto, J.M. (2006): Ultrastructural characterization of gills in juveniles of the Argentinian silverside, *Odontesthes bonariensis* (Valenciennes, 1835) (Teleostei: Atheriniformes). - *Anatomia Histologia Embryologia* 35: 76-83.
- [52] Zimmerli, S., Bernet, D., Burkhardt-Holm, P., Schmidt-Posthaus, H., Vonlanthen, P., Wahli, T., Segner, H. (2007): Assessment of fish health status in four Swiss rivers showing a decline in brown trout catches. - *Aquatic Sciences* 69: 11-25.