



ASSESSMENT OF FEMUR GEOMETRY FOR THE IMPLANT FABRICATION USING X- RAY ASSISTANCE OF PACS SYSTEM

G. Paramesh^{[a]*}, Rajitha Vanga^[b], Raja Siva^[c], Saravanan Sekaran^[d],
Dhanraj Ganapathy^[e]

Article History: Received: 26.05.2022

Revised: 25.06.2022

Accepted: 06.07.2022

Abstract: Proximal Femoral Geometry is subjected to wide range of ethnic variations. Various research article indicates that geometry of the proximal femur in the Indian population considerably differ from the European and American standard. The geometry of head, neck and the femoral stem is very essential in making of implants. Currently, arthroplasty components widely used in India are based on western standards, because of mismatched implant size there were several implications like joint congruence, micromotion, osteoarthritis, and tendinopathy. **Materials and methods:** Total 388 non - pathological hip joint X-rays collected from the Southern Indian population. The primary objective of the study is to measure proximal femoral geometry and compare the difference with various ethnic groups. Measurements like femoral head diameter, Neck width, Neck shaft angle, Femoral offset and Medullary canal diameter are calculated using Picture Archiving Communication System (PACS). **Results:** We have found the geometrically difference in proximal part of the femur in the south Indian population when compared with the geometries of femur worldwide. Furthermore, we have used sophisticated PACS system to measure the bony variations. The data femur will aid in fabrication of femur implants which will be precisely shaped and fit for the Indian population. **Conclusion:** The present study of the proximal femur in the south Indian population considerably differs from the dimensions of the Western ethnic population. The precise geometry of proximal femur helps clinicians to plan pre operative surgical procedure and also aid in development of proximal femoral hemiarthroplasty components which are suitable and fit for the Indian population

Keywords: Proximal Femur, Femoral head diameter, Anthropometry of Femur, Neck shaft angle, femoral implant, hemiarthroplasty.

[a]. Research scholar, Department of Anatomy, Vinayaka Mission's Kirupananda Variyar Medical College, Salem - 636308, Tamilnadu, India.

[b]. Assistant Professor, Department of Anatomy, Vinayaka Mission's Kirupananda Variyar Medical College, Salem- 636308, Tamilnadu, India.

[c]. Orthopedic Surgeon, ESIC hospital, Tirunelveli-627004, Tamilnadu, India.

[d]. Assistant Professor, Department of Prosthodontics, Saveetha Dental College, Chennai -60077.

[e]. Professor and Head, Department of Prosthodontics, Saveetha Dental College, Chennai -60077.

*Corresponding Author

Email: parameshanatomy94@gmail.com

DOI: 10.31838/ecb/2022.11.04.003

INTRODUCTION

The morphometry of femur and the acetabulum is a subject of discussion in the orthopedics research. The geometric dimensions described in the western population is quite different from the Indian population, the precise geometry of the femur aid in the design and development of femur component of hemiarthroplasty(Sahemey et al., 2021). Due to

availability of the precise data of western specific femur geometry, at present the designs, geometry of the femoral implants sizes are mostly available in western population. With no other data available in Indian ethnic currently the mismatched implants particularly design and developed for western ethnic with no other option employed in Indian ethnic(Rawal et al., 2012). The implants are of two types cemented implant which is of old generation used in osteonecrosis patients and osteoporosis patients while other type known as and uncemented implant which is of newer generation implant that does not used cementing material to fix, instead the implant employs quality of the design, shape and stability to fix with the shaft of the femur(Konan et al., 2019). While in India the most of the data that are available are mostly taken from the bones by using relatively outdated measuring tools like, goniometer, barren duck caliper, Boley gauge caliper, Castroviejo caliper. However to achieve precise data acquisition we had used X ray radiograph and the measurements were made using PACS software. The preciseness of digital measurement data is as high as conventional data acquisition. Furthermore, To minimize the post-operative, intra operative complications and the revision arthroplasty surgery, the arthroplasty components should be designed based on the anthropometry parameters of the Indian population. The study aims to get detailed parameters of the proximal femur and which will aid in the fabrication of implants.

MATERIALS AND METHODS

The study was conducted at Vinayaka Mission's Kirupananda Variyar Medical College, Salem, Tamilnadu. The study was conducted on 388 non-fractured antero- posterior X-ray pelvic radiographs of right and left side. The pelvic radiographs were taken by keeping the patients in supine with both limbs in neutral rotation. The measurements like Neck-shaft angle (NSA), Head diameter (HD), Neck Width (NW), Vertical offset (VO), Horizontal offset (HO), Medullary canal diameter at various levels. Measurements were taken using a picture archiving communication system (PACS) and for the accuracy of the measuring process, the radiograph optimized in full-screen view and the images magnified to the highest resolution and measurements were taken using Radiant DICOM software.

Inclusion criteria

All asymptomatic hip patients irrespective of sex who had undergone Lower Abdomen X-ray. age group 20-75 included.

Exclusion criteria

Patient with Osteoarthritis, rheumatoid arthritis, Tuberculosis, Osteoporosis, Osteonecrosis, Paget's disease, Hip dysplasia, Hip Impingement, tumors of hip like Osteosarcoma, Osteo myeloma Patients who had underwent either unilateral hemiarthroplasty, total hip arthroplasty, congenital deformities of hip

Head diameter

The femoral head diameter is measured by taking the largest superior-inferior diameter of the femoral head parallel to the transcervical and sub-capital line (Sengodan et al., 2017) (Figure 1)

Neck width

The narrowest part of the femoral neck parallel to the sub capital line and perpendicular to the neck shaft axis (Pathrot et al., 2016) (Figure 1)

Neck shaft angle

The femoral shaft axis is a line drawn by intersecting the midpoint of the transcervical line through equidistance points from the mediolateral surface of the femoral shaft center in the center of the medullary canal (Fischer et al., 2020) (Figure 2)

Horizontal offset

It is also known as femoral offset. It measures the distance between the femoral head to the tip of the greater trochanter (Roy et al., 2014) (Figure 3)

Vertical offset

Vertical offset is also called a femoral head position offset. Center of the femoral head to the apex of the lesser trochanter (Rai et al., 2021) (Figure 3)

Medullary canal diameter

Medullary canal diameter is measured in four different levels (Kumar et al., 2017)

1. Transverse diameter of the medullar canal at the level of apex of lesser trochanter (A)
2. 20 mm above the apex of lesser trochanter (B)
3. 20 mm below the apex of lesser trochanter (C)
4. 10 cm below the apex of lesser trochanter (D) (Figure 1)

Canal flare index

The canal flare index is calculated by the diameter of the medullary canal 20 mm above the apex of lesser trochanter (B) divided by 20 mm below the apex of lesser trochanter (C). based on the values of canal flare index the medullary canal isthmus

is classified normal (3-4.7), champagne flute (High tapering in the proximal segment 4.7-6.5), stovepipe (a straight proximal femur) (Saikia et al., 2008)

All the measurements are taken in the Research Lab, Department of Anatomy. To avoid error, the data was measured twice by the research supervisor.

Statistical Analysis

The statistical work was done using Graph pad Prism version 8.1.1. The statistical analysis includes Mean, standard deviation, range, Pearson coefficient.

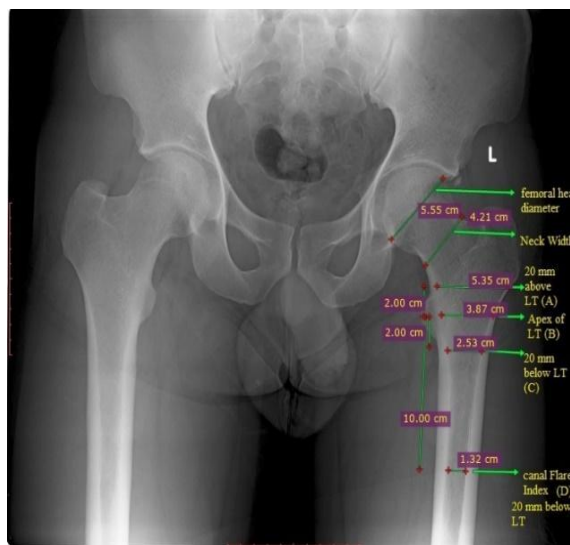


Figure 1. Sagittal X-ray of Hip showing femoral head diameter, Neck Width, Medullary canal diameter, Canal Flare Index

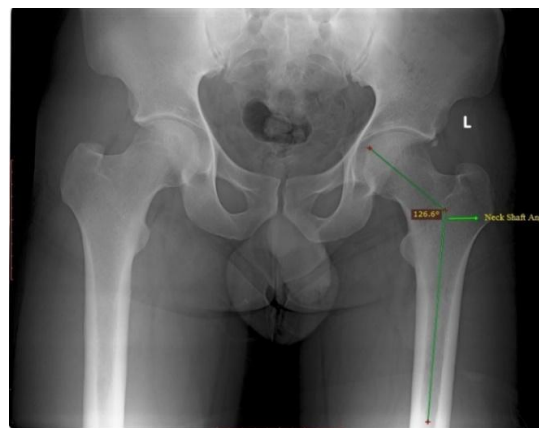

Figure 2. Sagittal X-ray of Hip showing Neck Shaft Angle

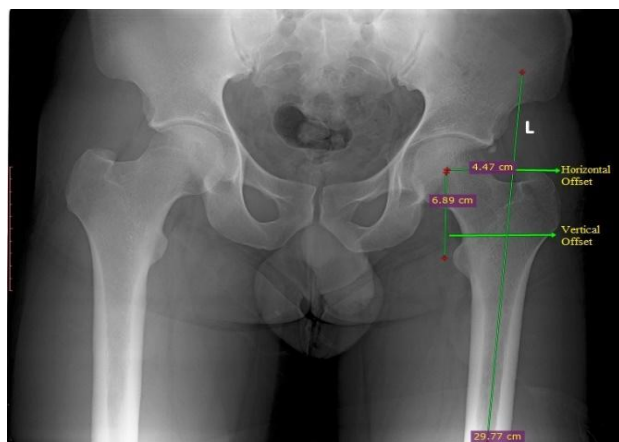


Figure 3. Sagittal X-ray of Hip showing Horizontal and Vertical axis

RESULTS

Femoral head diameter: The mean value of the femoral head diameter was 48.42 mm (Table 3). The mean value of the femoral head diameter in male was 52.07 mm and in female was 47.15 mm (Table 1). In males, the range of femoral head diameter was 23.3- 58.8 mm and in the female range of femoral head, the diameter was 40.5 - 56.6mm (Table 1). The gender difference Femoral head diameter was statistically significant (p<0.0002) (****). However, there is no statistical difference between right and left femoral head diameter (Table 2).

Neck width: The mean value of the femoral neck width was 35.53 mm (Table 3). The mean value of the neck width in male was 38.29 mm. and in female 32.80mm (Table 1). The minimum neck width in male was 30.29 and the maximum neck was 49.2 mm (Table 1). In the female range of the femoral neck, the width was 28.1-43.4 mm. The p-value of the neck width came statistically significant (p<0.0001) ****.

Neck shaft angle: The Neck shaft angle meanvalue was 128.96°. The mean value of the neck-shaft angle in males was 134.52° and in female neck-shaft angle was 128.40°. The value of neck shaft angle in male range between 119.8-155.2°and in female, the neck shaft angle range between 111.8°-151.1°. The p-value is highly significant (p<0.0001) ****.

Horizontal Offset: The mean value of the horizontal offset was 39.37mm (Table 3). For male, the mean of horizontal offset was 42.63 mm and in female mean value was 39.11 mm. The value of horizontal offset in the male range between 23.7 - 65 mm and in female the range between 23.3 -52 mm(Table 1). The p-value of male and female is statistically significant (p <0.0002) ***

Vertical offset: The mean value of the vertical offset was 58.16 mm (Table 3). The mean value of vertical offset male was 61.47 mm and the mean Vertical offset in female was 54.78 mm. The range of vertical offset in male was 44 -74.8 mm and in female range of vertical offset was 33.4 - 66.7 mm (Table 1). The vertical offset is significantly higher in male than female (p<0.0001) ****.

Medullary canal diameter: The mean value of the medullary canal at the level of apex of the lesser trochanter was 30.12 mm(Table -3). The mean value of the Medullary canal in male was 30.11 mm and in female was 28.89 mm. The mean value of medullary canal 20mm above the lesser trochanter (A)was 47.18 mm. In male medullary canal diameter 20 mm above lesser trochanter (A)was 48.41mm and female 47.15 mm. The canal diameter 20 mm below the lesser trochanter (B) in male was 23.62 mm and in female 21.86 mm (Table 1). The canal diameter 10 cm below the Lesser trochanter (B) was 15.25 mm (Table -3). The mean canal diameter 10 cm below Lesser trochanter (D) in male was 15.69 mm and 14.94 mm in female (Table 1)

Canal flare index: The mean canal flare index in male was 3.08 and in female was3.15. Based on the values of the canal flare index of the South Indian population classified as normal.

Table 1: Anthropometric parameters of male and female hip joints.

Parameters	Male			Female			p-value
	Mean	Standard Deviation	Range	Mean	Standard Deviation	Range	
Femoral head diameter	52.07	5.22	23.3 - 58.8	47.15	2.67	40.5 - 56.6	p<0.0002 ****
Neck width	38.29	3.53	30.80-49.2	32.80	5.63	28.1 -43.4	p<0.0001 ****
Neck shaft angle	134.52°	6.90	119.8° - 155.2°	128.40°	7.14	111.8° -151.1°	p>0.8
Horizontal Offset	42.63	9.6	23.7 -65	39.11	6.50	23.3 - 52	p<0.0001 ****
Vertical offset	61.47	6.99	44 - 74.8	54.78	4.56	33.4 -66.7	p<0.0001 ****
Medullary canal diameter (At the Apex of Lesser trochanter)	30.11	5.60	18.7 -59.9	28.89	5.89	15.7 - 37.7	p<0.08 ***
Medullary canal diameter (20mm above Lesser trochanter)	48.41	5.66	15.8 - 34.2	47.15	3.51	18.1 - 58.7	p<0.0001 ****

Medullary canal diameter (20mm below Lesser trochanter)	23.62	3.11	28.5 - 59.7	21.86	3.30	13.4 - 30.6	p<0.0001 ****
Medullary canal diameter (10 below Lesser trochanter)	15.69	5.60	10.1 - 50.8	14.94	2.77	10 - 33.5	p<0.04 **

Table 2: Anthropometric analysis of right and left Hip joint.

Parameters	side	Mean	Range	Standard deviation	p-value
Femoral head diameter	Right	48.73	24.3 - 58.6	5.11	p>0.8
	Left	48.71	23.3 - 58.8	5.79	
Neck width	Right	35.34	28.1 - 43.7	3.975971401	p>0.4
	Left	35.83	28.4 - 49.2	4.40	
Neck shaft angle	Right	128.20°	111.8° -151.1°	7.99	p>0.7
	Left	128.60°	117.8° -155.2°	7.10	
Horizontal Offset	Right	39.04	23.3 - 65	7.42	p>0.7
	Left	40.69	23.7 - 55.2	6.00	
Vertical offset	Right	57.64	33.4 - 74.8	8.00	p>0.3
	Left	58.71	42.6 - 74.6	7.00	
Medullary canal diameter (At the Apex of Lesser trochanter)	Right	29.96	18.7 - 59.9	5.69	p>0.2
	Left	29.12	15.7 - 37.8	4.49	
Medullary canal diameter (20mm above the Lesser trochanter)	Right	48.41	28.5 - 59.7	5.66	p>0.5
	Left	47.34	18.1 - 59.7	6.23	
Medullary canal diameter (20mm below the Lesser trochanter)	Right	22.61	13.4 - 34.2	3.78	p>0.5
	Left	22.88	15.1 - 29	3.05	
Medullary canal diameter (10 cm below the lesser trochanter)	Right	15.06	10 - 33.5	3.57	p>0.6
	Left	15.47	10.1 - 50.8	5.46	
	Left	35.58	22.9 - 49.3	4.40	

Table 3: Analysis of hip joint morphometry in various ethnic

Parameters	Rubin et al ^[13] (Swiss) n=32	Husmann et al ^[14] (France), n=310	Mahaisavariya et al ^[15] (Thai), n=108	Noble et al ^[16] (Caucasian), n=80	Asala et al ^[17] (South Africa) N=504	Saikia et al ^[10] (Indian), n=104	Rawal et al ^[2] (Indian), n=98	Sengodan et al ^[4] (Indian), n=400	Supree th et al ^[12] (Indian) n = 200	Present study n =388
Femoral head diameter	43.4±2.6	-	43.98±3.47	45.9	54.23	-	45.41±3.66	42.627.5	40.9	48.42
Neck width	-	-	-	-	-	-	-	27.5	28.29	35.53
Neck shaft angle	122.9°	129.2°	128.04°	125.4°	-	139.5°	124.42°	135.4°	130.68°	128.96°
Horizontal Offset	47	40.5	-	-	-	-	40.23	37.6	36.50	39.37
Vertical offset	56.1	57.3	48.94	-	-	-	52.33	46.9	49.20	58.16
Medullary canal diameter (At the Apex of Lesser trochanter)	27.9	-	-	-	-	-	-	20.2	26.14	30.12
Medullary canal diameter (20mm above Lesser trochanter)	-	-	-	-	-	-	-	-	-	47.18
Medullary canal diameter (20mm below Lesser trochanter)	-	-	-	-	-	-	-	-	-	22.04
Medullary canal diameter (10m below Lesser trochanter)	-	-	-	-	-	-	-	-	-	15.25

DISCUSSION

Anthropometry knowledge of proximal femur and acetabulum plays a vital role in better understanding the hip joint biomechanism. As socioeconomic reason and the various type of occupation has an important contribution in a morphological variation of the hip joint in male and female. In the present study comprehensive analysis of morphometry of proximal femur in the South Indian population using X-ray imaging and compared the difference with the other ethnic population. As morphometric data of proximal femur help us to evaluate the parameters of the western prosthesis as well as aid in the design and development of hemiarthroplasty components.

Femoral head diameter: The mean femoral head diameter in the South Indian population was 48.42 mm with compare to the swiss population was 43.4±2 mm (Rubin et al., 1992). Similarly mean femoral head diameter in Thai population was 43.98±3.47 mm (Mahaisavariya et al., 2002) . (Table 3). The mean femoral head diameter of Swiss and Thai populations is significantly smaller than the South Indian population . However, Asala et al 2001 in the south African study reports the femur head diameter was 54.23 mm which is geometrically larger than the present study (Asala, 2001) . Furthermore, we did not find the statistically difference between the right and left femur geometry (Table 2). The study by Rawal et al in the North Indian population shows that the mean femoral head diameter in North Indian Population is comparatively smaller than the present study conducted in South Indian population (Rawal et al., 2012). Anthropometry knowledge of the femoral head has an important clinical significance in the orthopedic literature. As improper size femoral head diameter may cause various clinical complications such as femoral head dysplasia and premature osteoarthritis.

Neck width: The mean neck width in the present study was 35.53 mm. Sengodan et al 2017 and Nekkanti et al 2020 (Nekkanti et al., 2020; Sengodan et al., 2017). of the South Indian population reported mean neck width was 27.5 mm and 28.29 mm (Table 3). However, present study of the South Indian population mean neck width is significantly larger than the similar studies done in the South Indian population. There is no significant difference in neck width between right and left proximal femur (Table 2). Variation of neck width between the male and female reported by Sengodan et al 2017 (Sengodan et al., 2017) Similar variation of neck width in male and female was observed in the present study was statistically significant $p < 0.0001$ ****. In female, as the age progresses bone rigidity gradually starts decreasing than the male. femoral neck width has an important indicator to analyze the bone rigidity and also aid in predict the hip fractures.

Neck shaft angle: The mean neck-shaft angle was 128.96° observed in the present study conducted in the South Indian population. The study reported by Husmann et al in France ethnic population, the mean neck-shaft angle was 129.2° (Husmann et al., 1997). Bo et al conducted a similar study in the Japanese ethnic population, the neck-shaft angle was 137°. The neck-shaft angle of the present study conducted in South Indian population is significantly smaller than the Japanese population (Bo et al., n.d.). Jalali Kondori et al 2017 in Iranian population reported, the mean Neck shaft angle is 139.5° These studies indicate that the mean neck-shaft angle in the present

study of South Indian population is significantly smaller than the western ethnic (Jalali Kondori et al., n.d.).

Horizontal and vertical offset: The horizontal offset helps in adduction, enhances the range of motion, reduces the crunches and limping. In the present study mean horizontal offset was 39.37mm. The mean Horizontal offset in male was 42.63 mm and in female 39.11 mm. The Horizontal offset is significantly larger than the female. However, there is no significant difference between the right and left proximal femur morphometry (Table 2). A similar study done by Rawal et al reported the mean horizontal offset was 40.23 mm of the North Indian population (Rawal et al., 2012)(Table 3). The horizontal offset of the study conducted in the present study of South Indian population is smaller than the North Indian population. However, other studies on western ethnic population have not reported the horizontal offset. The mean vertical offset in the present study was 58.16 mm. The vertical offset of the present study is larger than the similar study conducted by Mahaisavariya et al 2002 in Thai population (Mahaisavariya et al., 2002)(Table 3). The mean vertical offset in male was 61.47 mm and in female 54.78 mm(Table 1). The mean vertical offset of male is significantly larger than the female and $p < 0.0001$ **** value is statistically significant. However, there is no significant difference between the right and left vertical offset (Table 2).

Medullary canal diameter: Medullary canal diameter is used to decide the stem size during the selection of prosthesis and aid orthopedician to decide cemented or uncemented prosthesis .The medullary canal diameter was observed in four different levels 1) Mean canal diameter at the apex of lesser trochanter (B) was 30.12mm 2) Mean canal diameter 20 mm above the lesser trochanter (A) was 47.18 mm. 3) The mean canal diameter 20 mm below the lesser trochanter (C) was 22.04 mm and 4) 10 cm below the apex of lesser trochanter (D) was 15.25mm(Table 3).

In the present study canal diameter at the apex of lesser trochanter is significantly larger than the Swiss population reported by Nekkanti et al (Nekkanti et al., 2020) . However, the canal diameter 20 mm above and 20 mm below the lesser trochanter was not reported by other authors. Furthermore, there was statistical significance between the gender and there was no statistical difference between right and left medullary canal diameter at various levels.

Canal flare index: The diameter of the canal flare index decreases when age progresses, the present study reported an average canal flare index was 3.09. Based on the values of the present study of canal flare index, the medullary canal isthmus for the present study is classified as normal .

CONCLUSION

The present study comprehensively analyzed the anthropometry measurement of the proximal femur in male and female. The statistical data show male anthropometry measurements are larger than the female. But the average results showed femoral head in the present study was larger than the western ethnic population. Furthermore, the neck-shaft angle of the present study smaller than the other ethnic population.

Acknowledgments

We sincerely thank Dr.V.Rajitha, Assistant Professor, Department of Anatomy, Vinayaka Mission's Kirupananda Variyar Medical college.

Sincerely thank Dr. Rekha, Reader, Department of Anatomy, Nanda Dental College and Hospital, Erode, Tamilnadu

Sincerely thank Dr.Pushpa Burute, Professor, Head of the Department, Department of Anatomy BKL Walawalkar Rural Medical College and Hospital, Maharashtra, India.

Ethical approval: Obtained

Informed consent: Obtained

Funding sources: None

Conflict of interest: None

Authorship contributions: All the authors have contributed equally towards the conception of the study, research design, literature review, and manuscript preparation.

REFERENCES

- i. Asala, S. A. (2001). Sex determination from the head of the femur of South African whites and blacks. *Forensic Science International*, 117(1-2), 15–22.
- ii. Bo, Imura, Omori, Okumura, & Ando. (n.d.). Fit and fill analysis of a newly designed femoral stem in cementless total hip arthroplasty for patients with secondary osteoarthritis. *The Journal of Orthopaedic and Sports Physical Therapy*. <https://www.sciencedirect.com/science/article/pii/S0949265815337465>
- iii. Fischer, C. S., Kühn, J.-P., Völzke, H., Ittermann, T., Gumbel, D., Kasch, R., Haralambiev, L., Laqua, R., Hinz, P., & Lange, J. (2020). The neck-shaft angle: an update on reference values and associated factors. *Acta Orthopaedica*, 91(1), 53–57.
- iv. Husmann, O., Rubin, P. J., Leyvraz, P. F., de Roguin, B., & Argenson, J. N. (1997). Three-dimensional morphology of the proximal femur. *The Journal of Arthroplasty*, 12(4), 444–450.
- v. Jalali Kondori, Asadi, & Bahadoran. (n.d.). Anthropometric study of hip joint in tehran population using computed tomography scan. *Anatomical Sciences Education*. http://anatomyjournal.ir/browse.php?a_id=191&slc_lang=en&sid=1&printcase=1&hbnr=1&hmb=1
- vi. Konan, S., Abdel, M. P., & Haddad, F. S. (2019). Cemented versus uncemented hip implant fixation: Should there be age thresholds? *Bone & Joint Research*, 8(12), 604–607.
- vii. Kumar, A., Venkatesh Kumar, N., S., U., & Noel, C. (2017). Assessment of proximal femur anthropometry in South Indian population through cadaveric bones and radiologically correlating difference if any between other ethnic groups. In *International Journal of Research in Orthopaedics* (Vol. 3, Issue 3, p. 466). <https://doi.org/10.18203/issn.2455-4510.intjresorthop20171576>
- viii. Mahaisavariya, B., Sitthiseripratip, K., Tongdee, T., Bohez, E. L. J., Vander Sloten, J., & Oris, P. (2002). Morphological study of the proximal femur: a new method of geometrical assessment using 3-dimensional reverse engineering. *Medical Engineering & Physics*, 24(9), 617–622.
- ix. Nekkanti, S., Moogali, A., Mahtani, A., & Mruthyunjaya. (2020). A comparative analysis of morphological parameters in south indian hip joints with review of literature. *Journal of the Anatomical Society of India*, 69(2), 71.
- x. Pathrot, D., Ul Haq, R., Aggarwal, A. N., Nagar, M., & Bhatt, S. (2016). Assessment of the geometry of proximal femur for short cephalomedullary nail placement: An observational study in dry femora and living subjects. *Indian Journal of Orthopaedics*, 50(3), 269–276.
- xi. Rai, A. K., Yadav, S., Verma, V., Anand, S., & Shekhar, S. (2021). Analysis of vertical and horizontal offsets in displaced femoral neck fracture in elderly treated with indigenous bicentric bipolar hip device. *Journal of Clinical Orthopaedics and Trauma*, 13, 143–146.
- xii. Rawal, B., Ribeiro, R., Malhotra, R., & Bhatnagar, N. (2012). Anthropometric measurements to design best-fit femoral stem for the Indian population. *Indian Journal of Orthopaedics*, 46(1), 46–53.
- xiii. Roy, S., Kundu, R., Medda, S., Gupta, A., & Nanrah, B. K. (2014). Evaluation of proximal femoral geometry in plain anterior-posterior radiograph in eastern-Indian population. *Journal of Clinical and Diagnostic Research: JCDR*, 8(9), AC01–AC03.
- xiv. Rubin, P. J., Leyvraz, P. F., Aubaniac, J. M., Argenson, J. N., Estève, P., & de Roguin, B. (1992). The morphology of the proximal femur. A three-dimensional radiographic analysis. *The Journal of Bone and Joint Surgery. British Volume*, 74(1), 28–32.
- xv. Sahemey, R., Moores, T. S., Meacher, H., Youssef, B., Khan, S., & Evans, C. R. (2021). Anthropometric method for estimating component sizes in total hip arthroplasty. *World Journal of Orthopedics*, 12(11), 859–866.
- xvi. Saikia, K. C., Bhuyan, S. K., & Rongphar, R. (2008). Anthropometric study of the hip joint in northeastern region population with computed tomography scan. *Indian Journal of Orthopaedics*, 42(3), 260–266.
- xvii. Sengodan, V. C., Sinmayanatham, E., & Kumar, J. S. (2017). Anthropometric analysis of the hip joint in South Indian population using computed tomography. *Indian Journal of Orthopaedics*, 51(2), 155–161.