



# ALTERATIONS IN ADULT MOUSE TESTIS AFTER SUBACUTE INTOXICATION WITH CADMIUM AND MONENSIN DETOXICATION

Ekaterina Pavlova<sup>[a]</sup>, Juliana Ivanova<sup>[b]</sup>, Donika Dimova<sup>[a]</sup>,  
Yordanka Gluhcheva<sup>[a]</sup>, Nina Atanassova<sup>[a]</sup>

Paper was presented at the 4<sup>th</sup> International Symposium on Trace Elements in the Food Chain, Friends or Foes, 15-17 November, 2012, Visegrád, Hungary

**Keywords:** cadmium intoxication, monensin, *in vivo* model, testis morphology

Cadmium (Cd) is a heavy metal and a major environmental pollutant. The general population is exposed to Cd mainly via drinking water and food products. We have developed a mouse experimental model to investigate the *in vivo* effects of Cd and the chelating agent monensin on testis and sperm count during adulthood. Animals were divided into three groups: normal control (receiving distilled water and food): Cd group, exposed to 20 mg kg<sup>-1</sup> b.w. Cd(II) acetate for the first 2 weeks of the experimental period and Cd+monensin group, receiving monensin (18 mg kg<sup>-1</sup>) after Cd-intoxication (from 15<sup>th</sup> to 28<sup>th</sup> day). Histological observations of the testis demonstrated that Cd induced desquamation of germ cell and their assembly in the luminal region of the tubules. Areas in the testis without spermatides in latest steps of differentiation were also observed in this group. Monensin administration to Cd-treated animals restored histology of the testis to normal to a great extent (despite some Sertoli-cell-only tubules). Statistically significant changes in sperm count were not established for any of the experimental groups. Monensin can reduce injury of the testis and normalize its morphology after subacute exposure to Cd. The results of the present study demonstrated that monensin is a good compound in chelating therapy of some heavy metal intoxications.

Corresponding Author: Ekaterina Pavlova

Fax: +359 2 871 01 07

E-Mail: [e\\_bankova@yahoo.com](mailto:e_bankova@yahoo.com)

[a] Institute of Experimental Morphology, Pathology and Anthropology with Museum, Bulgarian Academy of Sciences, Acad. Georgi Bonchev Str., bl. 25 Acad. Georgi Bonchev Str., bl. 25, 1113 Sofia, Bulgaria

[b] Faculty of Medicine, Sofia University "St. Kliment Ohridski", Kozjak 1 Kozjak 1, 1407 Sofia, Bulgaria

for treatment of Cd intoxication. Recent studies have been demonstrated that polyether ionophore antibiotic, monensin is much more effective than the traditional chelators as EDTA (ethylenediaminetetraacetic acid) and DMSA (meso-dimercapto-succinic acid) in reducing lead (Pb) concentrations. Tetraethylammonium salt of monensic acid forms complexes with other toxic metal ions as Li<sup>+</sup>, Na<sup>+</sup>, Cd(II) and Hg(II), suggesting that could be applied for treatment of intoxications with these metals.<sup>7,8</sup>

## Introduction

Cadmium (Cd) is a heavy metal and an environmental contaminant mostly found in tobacco smoke and industrial pollution, but also in water and food chain.<sup>1</sup> Cd is also bio-accumulative due to its long biological half-life and depending on its dose, route and duration of exposure it can affect target organs such as kidney, liver, lung, testis, adrenals, adipose tissue and hemopoietic system.<sup>2,3</sup> Cd induces apoptosis and affects cell proliferation, differentiation and other cellular activities (gene expression, signal transduction, DNA repair and DNA methylation). Co interferes with enzymes of the cellular antioxidant system and generates of reactive oxygen species (ROS).<sup>4</sup> In fact, the International Agency for Cancer Research classified cadmium as the 7<sup>th</sup> toxicant in the priority list of Hazardous Substances<sup>5</sup>.

Chelation therapy is the preferred medical treatment of reducing the toxic effects of metals. Chelating agents are capable of binding to toxic metal ions to form complex structures which are easily excreted out from the body removing them from intracellular or extracellular spaces<sup>6</sup>. Different compounds have been tested as chelating agents

The aim of our study was to investigate the *in vivo* effects of Cd and the chelating agent monensin on the testis and sperm count in adulthood.

## Materials and Methods

60-day old adult male ICR mice were fed a standard diet and had access to food *ad libitum*. Mice were maintained in the institute's animal house at 23°C ± 2 °C and 12:12 h light - dark cycle in individual standard hard bottom polypropylene cages. The animals were left to acclimatize for one week prior to dosing.

Mice were divided into three groups: The first group was a control and had free access to distilled water and food during the experimental period. The second group was subjected to subacute Cd(CH<sub>3</sub>COO)<sub>2</sub>·2H<sub>2</sub>O intoxication with daily dose of 20 mg kg<sup>-1</sup> b.w. for two weeks. The compound was dissolved and prepared with distilled water. In the next 14 days of the experiment the animals from this group obtained distilled water and food *ad libitum*. The third group was exposed to Cd intoxication as that of the second group followed by treatment with tetraethylammonium salt of monensic acid at daily dose of 18 mg kg<sup>-1</sup> b.w. from day 15 to day 28 of the experimental process.

On day 29 the experimental mice were sacrificed. Testes and epididymides were sampled, weighed and embedded in paraffin using routine histological practice. Spermatozoa were isolated from both vasa deferentia and counted using Buerker's chamber. Data were statistically processed using Student's t-test.

## Results

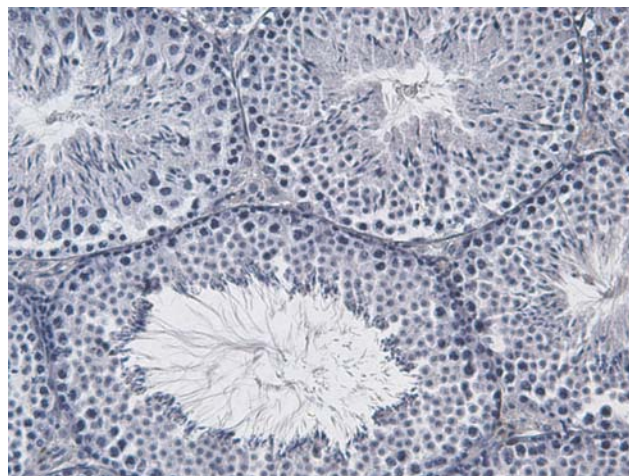
On day 90 spermatogenesis in mouse is completed, and all the stages of the spermatogenic cycle can be seen. Germ cells are organized in twelve stages according to the classification of Clermont and Perey<sup>9</sup> arranged in 5-6 layers in seminiferous epithelium. Mature spermatozoa are released into the tubular lumen in stages VII-VIII of the cycle (Figure 1). Histological observation of testes after subacute Cd intoxication demonstrated disorganization of seminiferous epithelium. Germ cells were sloughed off from the seminiferous epithelium and were located in the luminal region of the tubules. Seminiferous tubules devoid of spermatides in latest steps of differentiation were frequently observed in this group (Figure 2). After monensin administration of Cd intoxicated animals we established restoration of normal morphology of the testis to a great extent (Figure 3) despite Sertoli-cell-only tubules at some places. In contrast to our expectations at this stage of the experiment we did not establish significant negative alterations of Cd acetate on gonado-somatic index (calculated as a ratio of testis weight to body weight) or sperm count in adult mice (data not shown).

## Discussion

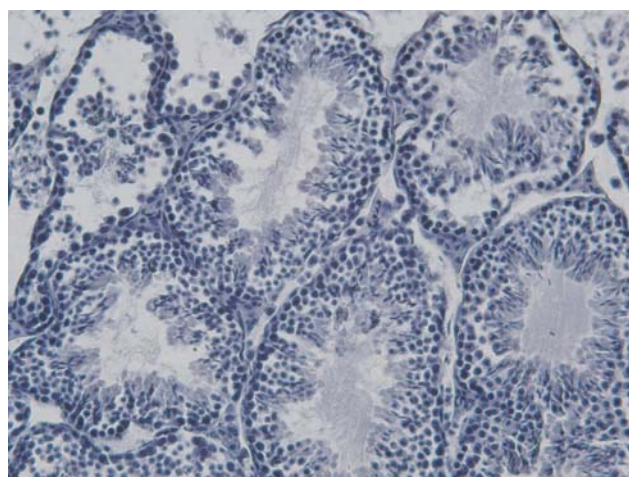
After subacute Cd intoxication of adult mice we observed pathological changes of testis morphology. Our data regarding the germ cell loss is supported by the findings of Siu et al.<sup>9</sup>. Cd exerts its effect in the testis by perturbing blood-testis barrier function, affecting germ cell adhesion in the seminiferous epithelium that probably explains germ cell loss and disorganization of the epithelium. In male rodents, it is well established that Cd works as endocrine disruptor by affecting the synthesis and regulation of several hormones (testosterone, LH, FSH)<sup>10</sup>. For instance, a significant decrease in serum and testicular testosterone level was reported in mice exposed to acute doses of Cd compounds illustrating that Cd can disrupt the hypothalamic-pituitary-testicular axis by creating a hormonal disbalance and affecting male fertility.<sup>11</sup> Manipulation of androgen (or of the androgen receptor in Sertoli cells) can be a potential target candidate to manage Cd-induced testicular toxicity<sup>3</sup>. Moreover, Cd-induced toxicity has been associated with generations of reactive oxygen species (ROS)<sup>12</sup>. Spermatogenesis is a sensitive process and changes in hormonal levels or elevation of ROS would influence the normal proceeding of spermatogenesis and the structure of seminiferous epithelium.

The work already done by our group<sup>12</sup> demonstrated significant increase in Cd accumulation in all investigated organs (liver, kidney, spleen, lung, heart and testes) in Cd-intoxicated animals. The administration of tetraethylammonium salt of monensic acid to Cd-treated animals depleted Cd concentrations to a great extent in all

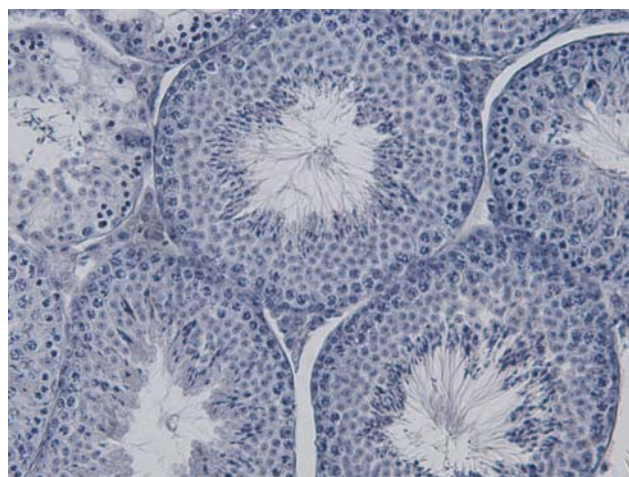organs as compared to Cd-intoxicated mice. In the testis Cd content was reduced with 55% as compared to Cd-treated group. These results are in agreement with the good chelating effects of monensin on testis histology.



**Figure 1.** Morphology of the seminiferous tubules on control testis cross sections of adult mice. HE, x 400.



**Figure 2.** Morphology of the seminiferous tubules on testis cross sections of adult mice after subacute Cd intoxication ( $20 \text{ mg kg}^{-1} \text{ b.w.}$ ) Disorganization of seminiferous epithelium was observed. HE, x 400.



**Figure 3.** Restoration of normal morphology of the testis to a great extent after chelating therapy with monensin ( $18 \text{ mg kg}^{-1} \text{ b.w.}$ ) of Cd intoxicated mice ( $20 \text{ mg kg}^{-1} \text{ b.w.}$ ). HE, x 400.

We found that Cd accumulation in the testis had no effect on testicular weight. The data by Teiichiro et al.<sup>13</sup> and Haouem et al.<sup>14</sup> support our results while El-Demardash et al.<sup>15</sup> observed that Cd decreased this parameter. Blanco et al.<sup>16</sup> reported that Cd caused a decrease in testicular weight at concentration in the testis of about 1 µg g<sup>-1</sup>. This value is much higher than the concentration of Cd observed in the testes of our experimental animals<sup>12</sup> which could be a possible explanation for the lack of effect on gonado-somatic index. Usually, impaired spermatogenesis is associated with reduced testis weight and low sperm count. Haouem et al.<sup>14</sup> established that sperm concentration was comparable between control and Cd-contaminated rats after 4<sup>th</sup> and 8<sup>th</sup> weeks of treatment, while after 12 weeks of exposure this parameter was significantly decreased in Cd-treated animals compared to corresponding control. Probably the effect of Cd on sperm production depends on the duration of the treatment and therefore prolonged treatment would induce changes not only on histological level but also on quantitative parameters of mice spermatogenesis.

## Conclusion

Our investigations demonstrated that subacute Cd intoxication induced severe changes in testis morphology but not in the gonado-somatic index and epididymal sperm count. Monensin reduced testis injury and recovered its morphology to a great extent that can suggest monensin as a favorable compound in chelating therapy of some heavy metal intoxications.

**Acknowledgements:** The financial support of this work by the University of Sofia "St. Kliment Ohridski" Fund for Scientific Research (grant 72/2012, project leader: Juliana Ivanova) is acknowledged.

## References

- <sup>1</sup>IARC Monographs. International Agency for Research on Cancer, **1993**, Lyon, France.
- <sup>2</sup>Waalkers, M.P., *Mutat. Res.*, **2003**, 533, 107.
- <sup>3</sup>Siu, E. R. Mruk, D. D., Porto, C. S., Yan Cheng, C. *Toxicol. Appl. Pharm.*, **2009**, 238, 240.
- <sup>4</sup>Waisberg, M., Joseph, P., Hale, B., Bayersmann, D. *Toxicology*, **2003**, 192, 95.
- <sup>5</sup>Thompson, J., Bannigan, J. *Reprod. Toxicol.*, **2008**, 25, 304.
- <sup>6</sup>Swaran, J. S., Pachauri, F., Pachauri, V. *Int. J. Environ. Res. Pub. Health* **2010**, 7(7), 2745.
- <sup>7</sup>Hamidinia, S.A., Shimelis, O.I. Tan, B., Erdahl, W.L., Chapman, C. J., Renkes, G. D., Tavlör, R. W., Pfeiffer, D. R. *J. Biol. Chem.* **2002**, 277(41), 38111.
- <sup>8</sup>Singh, M., Kalla, N. R., Sanyal, S. N. *Pharmacol. Reports*, **2007**, 59, 456.
- <sup>9</sup>Clermont, Y., Perey, B. *Am. J. Anatomy*. **1957**, 100 (2), 241.
- <sup>10</sup>Lafuente, A., Gonzalez-Carracedo, A., Romero, A., Cano, P., Esquifino, A. I., *Toxicol. Lett.* **2004**, 146, 175.
- <sup>11</sup>Mruk, D. D., Yan Cheng, C. *Landes Biosci.*, **2011**, 1(4), 283.
- <sup>12</sup>Ivanova, J., Gluhcheva, Y.G., Kamenova, K., Arpadjan, S., Mitewa, M. *J. Trace Elem. Med. Biol.* **2012**, in press.
- <sup>13</sup>Teiichiro, A., Hirmichi, I., Keisuke, M., Kunihiro, H., Makoto, H. *Reprod. Med. Biol.* **2002**, 1, 59.
- <sup>14</sup>Haouem, S., Najjar, M.F., El Hani, A., Sakly, R. *Exp. Toxicol. Pathol.* **2008**, 59, 3007.
- <sup>15</sup>El-Demardash, F. M., Yousef, M. I., Kedwany, F. S., Bagdadi, H. *H. Food Chem. Toxicol.* **2004**, 42, 563.
- <sup>16</sup>Blanco, A., Moyano, R., Vivi, J., Frores-Acuna, R. Molina, A., Blanco, C. et al. *Environ. Toxicol. Pharmacol.* **2007**, 23, 96.

Received: 15.10.2012.

Accepted: 13.11.2012.



